



## Neuroanatomical markers of speaking Chinese

Journal:	<i>Human Brain Mapping</i>
Manuscript ID:	HBM-08-0424.R2
Wiley - Manuscript type:	Research Article
Date Submitted by the Author:	29-Apr-2009
Complete List of Authors:	Crinion, Jenny; University College London, Wellcome Trust Centre for Neuroimaging Green, David; University College London, Division of Psychology and Language Sciences Chung, Rita; University College London, Wellcome Trust Centre for Neuroimaging Ali, Nilufa; University College London, Division of Psychology and Language Sciences Grogan, Alice; University College London, Wellcome Trust Centre for Neuroimaging Price, Gavin; University College London, Wellcome Trust Centre for Neuroimaging Mechelli, Andrea; Kings College London, Institute of Psychiatry; University College London, Wellcome Trust Centre for Neuroimaging Price, Cathy; University College London, Wellcome Trust Centre for Neuroimaging
Keywords:	Tonal Language, Structural anatomy, Multilingual, Gray matter, White Matter, Chinese



*Neuroanatomical markers of speaking Chinese***Neuroanatomical markers of speaking Chinese**

Crinion, J.\*<sup>^</sup>, Green, D.W.<sup>†</sup>, Chung, R.\*<sup>\*</sup>, Ali, N.<sup>†</sup>,  
Grogan, A.\*<sup>\*</sup>, Price, G.\*<sup>\*</sup>, Mechelli, A.\*<sup>⌘</sup>, Price, C.J.\*<sup>\*</sup>

\* Wellcome Trust Centre for Neuroimaging, University College London, UK.

<sup>†</sup> Division of Psychology and Language Sciences, University College London, UK.

<sup>⌘</sup> Institute of Psychiatry, Kings College London, UK.

<sup>^</sup> Institute of Cognitive Neuroscience, University College, London, UK.

**Corresponding author:**

Jenny Crinion\*<sup>^</sup>,  
Wellcome Trust Centre for Neuroimaging  
12 Queen Square,  
London WC1N 3BG,  
UK.  
Telephone/Fax: +44 (0)20 7833 7472/ (0)20 7813 1420  
Email: [j.crinion@ucl.ac.uk](mailto:j.crinion@ucl.ac.uk)

**Running Title:**

Neuroanatomical markers of speaking Chinese

**Key words:**

1. Structural anatomy;
2. Gray matter;
3. White matter;
4. Tonal language;
5. Chinese;
6. Multilingual.

*Neuroanatomical markers of speaking Chinese***Abstract**

The aim of this study was to identify regional structural differences in the brains of native speakers of a tonal language (Chinese) compared to non-tonal (European) language speakers. Our expectation was that there would be differences in regions implicated in pitch perception and production. We therefore compared structural brain images in three groups of participants: 31 who were native Chinese speakers; 7 who were native English speakers who had learnt Chinese in adulthood and 21 European multilinguals who did not speak Chinese. The results identified two brain regions in the vicinity of the right anterior temporal lobe and the left insula where speakers of Chinese had significantly greater gray and white matter density compared with those who did not speak Chinese. Importantly the effects were found in both native Chinese speakers and European subjects who learnt Chinese as a non-native language, illustrating that they were language related and not ethnicity effects. On the basis of prior studies, we suggest that the locations of these gray and white matter changes in speakers of a tonal language are consistent with a role in linking the pitch of words to their meaning.

*Neuroanatomical markers of speaking Chinese***Introduction**

Natural languages share common properties. They use words, syntax and prosody to communicate meanings. It is therefore reasonable to suppose that the neural regions that process lexical meaning, syntax and prosody in one language do so in another. However, there are also differences between languages that are likely to have consequences on brain structure and function. Identifying these consequences is important on both theoretical and practical grounds in order to understand how the language network adapts to distinct requirements and to predict the effects of regional damage. A strong contrast is between tonal languages (e.g. Chinese) that use pitch to signal differences in word meaning and non-tonal languages (e.g. European languages) that do not. We asked two questions: What regional structural differences exist in the brain of native speakers of a tonal language compared to non-tonal language speakers? Prior research provides clues but no definitive answers to this question. Second, if a tonal language is acquired as a non-native language do the same regional brain differences emerge? This question has not been addressed before to our knowledge.

Our study focuses on structural brain differences that reflect the long-term use of a tonal language. To do this we compared brain structure in groups of subjects who do, and do not, speak Chinese. Differences in the local brain tissue composition were extracted using voxel based morphometry (VBM) after eliminating macroscopic differences in brain shape and controlling for ethnicity and number of languages. Prior research indicates that both cognitive and motor abilities can correlate with differences in brain structure e.g., [Gaser and Schlaug 2003; Lee et al. 2007; Maguire et al. 2000; Draganski and May 2008; Mechelli et al. 2004] and so we expected that

*Neuroanatomical markers of speaking Chinese*

there would be structural brain differences between tonal and non-tonal language speakers. The advantage of using structural imaging is that, unlike functional imaging, the interpretation does not depend on the stimuli, task or ability to perform the task in the scanner.

Our expectation was that the brains of Chinese and non-Chinese speakers would differ in regions implicated in pitch perception and production. In Mandarin, for instance, there are four different tones that differ in pitch height and the shape of the pitch contour. To illustrate, the syllable /ma/ means “mother” when spoken in one tone but a reproach when spoken in another. Understanding and producing speech in a tonal language such as Chinese requires binding together pitch information with syllabic information. We expected therefore that structural brain changes should reflect the ability in tonal language speakers to track the pitch contour of continuous speech and simultaneously bind it with syllabic information, a skill non-tonal language speakers do not have. What regions might be involved? Lesion studies [Zatorre and Samson 1991] suggest that regions in the right hemisphere (right temporal and right frontal) but not in the left hemisphere are important for the retention of pitch information with the right anterior temporal region especially relevant in judging pitch constancy [Warrier and Zatorre 2004]. Functional neuroimaging studies also indicate the importance of right temporal activation in tasks involving pitch processing in normal subjects e.g., [Warren et al. 2003a; Patterson et al. 2002]. For example, regions anterior to Heschl’s gyrus (HG) in the right superior temporal cortex have been associated with voice pitch processing e.g., to identify gender, and the speaker’s affective state, while voice spectral information is processed in posterior parts of the superior temporal gyrus (STG) and areas surrounding the planum parietale (PP) bilaterally e.g.

*Neuroanatomical markers of speaking Chinese*

to determine a speaker's identity [Lattner et al. 2005]. However, these studies did not investigate pitch processing in the context of comprehension and production of a tonal language.

The importance of the left rather than right hemisphere for discriminating tone for lexical purposes has been highlighted by studies of Chinese speaking patients with aprosodia [Hughes et al. 1983], behavioural studies of normal subjects [ e.g., Wang et al. 2001] and neuroimaging studies [Gandour et al. 2000];[ Gandour et al. 2003] ;[Hsieh et al. 2001];[Wong et al. , 2004]; { Wang et al.2003}. See Zatorre and Gandour, 2008 for a recent integrative review of the topic. Neuroimaging studies of connected speech in Chinese are scarce but there are cross-language studies on sentence level prosody and tone that report right rather than left lateralized activation. Tong and colleagues [Tong et al. 2005] found rightward asymmetries in the middle frontal gyrus (MFG) in both Chinese and English subjects during the discrimination of sentence-level prosodic phenomena in Mandarin Chinese. Likewise, Gandour et al. (2004) found right MFG and right superior temporal sulcus (STS) activations in both Chinese and English subjects processing Mandarin tone and intonation in syllable utterance pairs. As these effects were common to both Chinese and English subjects, the authors suggest that pitch processing for lexical meaning is left lateralized but pitch processing for non-lexical processing i.e. speech prosody perception is mediated primarily by the right hemisphere. However, the mismatch negativity (MMN) data from Luo and colleagues [Luo et al. 2006] suggest a slightly different interpretation. They demonstrated that early auditory processing of a lexical tone at a preattentive stage is actually lateralized to the right hemisphere in native Mandarin Chinese speakers. In the same subjects varying the initial consonants of the

*Neuroanatomical markers of speaking Chinese*

1  
2  
3  
4  
5  
6  
7  
8  
9  
10  
11  
12  
13  
14  
15  
16  
17  
18  
19  
20  
21  
22  
23  
same consonant-vowel structure produced an opposite pattern. Given the distinct acoustic features between a lexical tone and a consonant, this opposite lateralization pattern suggests the dependence of right versus left hemisphere mainly on acoustic cues before speech input is mapped into a semantic representation in the processing stream. This would suggest that both hemispheres are important for tonal language identification recruiting both left dominant language systems and right hemisphere acoustic systems. Further, as Zatorre and Gandour (2008) argue, it is probable that linguistic status modulates processing at many points before access to word meaning.

Structural imaging offers an alternative perspective on the brain regions mediating the processing of a tonal language. To our knowledge there has been one prior structural study. Kochunov and colleagues [Kochunov et al. 2003] examined brain differences between English-speaking Caucasians and Chinese-speaking Asians. They identified global surface differences in brain shape using deformation field morphometry that they attributed to the acquisition of a tonal language. However, these surface differences may reflect differences in ethnicity or in the number of languages spoken by their two groups. Hence we sought to identify whether there were any structural brain differences between tonal and non-tonal language speakers in brain regions implicated in pitch perception and production, controlling for ethnicity and number of languages spoken. If regional gray or white matter density differences were found only in the native Chinese speakers then the effects could be attributed to ethnicity alone. However, if regional gray or white matter density was significantly greater in both native and non-native Chinese speaking groups, then the effect would more likely be a consequence of speaking a tonal language. Our expectation was that the

*Neuroanatomical markers of speaking Chinese*

same regional differences would be evident in native and non-native speakers of Chinese because acquisition would recruit components of a common network.

**Materials and Methods**

The study was approved by the National Hospital and Institute of Neurology's joint medical ethics committee.

*Participants*

Fifty-nine right handed volunteers (between 18-29 years of age), neurologically normal, MRI compatible and proficient in English and Chinese or at least one other language were included. In London, most proficient multilingual speakers acquire English as their second language. Consequently, we had more volunteers who spoke English as their non-native language (n=52) than English as their native language (n=7). Each participant was assigned to one of three groups depending on their ability to speak our target tonal language (Chinese) or not. The first group comprised 21 European multilinguals that never learnt Chinese, another tonal or a pitch accent language. All spoke English as their non-native language and their first languages were German (n = 8), Greek (n = 11), and Portuguese (n = 2). The second group comprised 31 native Chinese multilinguals that learnt English. The third group comprised seven native English multilinguals who were late learners of Chinese, studying Mandarin at the School of Oriental and African Studies in London.

As shown in Table 1, all three multilingual groups were well matched for age and number of languages spoken. As per convention, all subjects completed a language history questionnaire (cf; Li, Sepanski & Zhao, 2006) allowing us to screen the subjects' eligibility to take part in the study. The 7 native English participants all

*Neuroanatomical markers of speaking Chinese*

1  
2  
3  
4  
5  
6  
7  
8  
9  
10  
11  
12  
13  
14  
15  
16  
17  
18  
19  
20  
21  
22  
23  
learnt Chinese through formal university instruction and reported it to be the dominant foreign language they used at the time of this study. All were full time Masters students learning Mandarin at SOAS, University of London. For this course, they had to read and write Chinese articles and speak Chinese with classmates. Three subjects had travelled and lived in China for more than 3 months. As a group they had used Chinese on average for 2 years [range 1-4 years, s.d. 1.1 years]. Their self rating of proficiency in Chinese was good overall with writing Chinese being their least proficient skill and speaking Chinese being their most proficient skill.

All non-native English speaking subjects were residents in the UK and reported English to be their dominant language of daily use. All learnt English mainly through formal classroom instruction (4 Chinese and 4 Europeans also learnt English at home) and all rated English as their most proficient foreign language. The native Chinese speakers spoke English for a mean of 13.8 years [range 3-20 years, s.d. 4.6 years] while the non-Chinese speaking group: mean=15.4 years, range 1-23 years, s.d. 3.8 years.

Table 1 about here

*Behavioural Assessments*

43  
44  
45  
46  
47  
48  
49  
50  
51  
52  
53  
54  
55  
56  
57  
58  
59  
60  
As an index of English and Chinese fluency at the single word and connected speech levels, we administered a verbal fluency task and a composite picture description task on the same occasion as MRI scanning. The verbal fluency task is a standard clinical test for single word production. The composite picture description task is commonly used to elicit speech at the sentence level. Ten participants from the native Chinese group and one participant from the non-native participant group did not complete these additional behavioral assessments. The results for the Chinese version of these

*Neuroanatomical markers of speaking Chinese*

1  
2  
3  
4  
5  
6  
7  
8  
9  
10  
11  
12  
13  
14  
15  
16  
17  
18  
19  
20  
21  
22  
23  
24  
25  
26  
27  
28  
29  
30  
31  
32  
33  
34  
35  
36  
37  
38  
39  
40  
41  
42  
43  
44  
45  
46  
47  
48  
49  
50  
51  
52  
53  
54  
55  
56  
57  
58  
59  
60

tasks were therefore collected from 21/31 native Chinese speakers and 6/7 non-native Chinese speakers. The results from the English versions of these tests were collected from the same 27 subjects (21 native and 6 non-native Chinese speakers) and also from the 21 Europeans who did not speak Chinese. Additional assessments of English vocabulary knowledge and reading abilities (in all English speaking participants) were assessed with the Lexical Decision Test from the Psycholinguistic assessment of language processing in aphasia (PALPA)[Kay et al. 2001] and the English Vocabulary Test[Meara 1992]. This confirmed that the Chinese and European multilingual participants were also matched for their English language abilities (see Table 1).

In the verbal fluency task, participants named as many items as possible within a minute beginning with a given phoneme e.g., /s/. Different phonemes were used in the Chinese and English version of the task (counterbalanced across the native and non-native speakers of Chinese). The important point to note is that, although there was a wide range of fluency scores within group, there was no significant group difference in Chinese fluency (Mann-Whitney  $U = 46.5$ ,  $z < 1$ ) between the native Chinese speakers (Mean/SD = 8.6/3.8) and the non-native Chinese speakers (Mean/SD = 13.5/10.4). The critical analytic point is that both Chinese speaking groups demonstrate proficiency in Chinese that is sufficient to warrant our categorical, between group comparison. We also note that fluency score was not significantly correlated with the number of languages spoken on either the English fluency tests ( $r=0.3$ ,  $p=0.1$ ) or Chinese fluency tests ( $r=-0.3$ ,  $p=0.2$ ).

*Neuroanatomical markers of speaking Chinese*

In the picture description task, participants described a picture for one minute. The pictures were taken from the Comprehensive Aphasia Test (CAT: [Swinburn et al. 2005]) and the Boston Diagnostic Aphasia Examination (BDAE: [Goodglass and Kaplan 1972]). Different pictures were used in the Chinese and English version of the task (counterbalanced across native and nonnative speakers of Chinese). The picture descriptions were scored, as per the CAT manual by a native Chinese speaker who was also fluent in English from an early age. The picture description score covered both content and manner of expression thereby providing a test for both semantic and syntactic knowledge. The content measure is the sum of appropriate information carrying words minus inappropriate information carrying words. To this are added values for syntactic variety (on a scale of 0 to 6), grammatical well-formedness (on a scale of 0 to 6) and speed of speech production (on a scale of 0-3). As might be expected, the overall score was significantly higher (Mann-Whitney  $U = 15.00$ ,  $Z = 2.81$ ,  $P < 0.01$ ) for the native Chinese speaking group (Mean/SD = 18.8/5.1) than the non-native Chinese speaking group (Mean/SD = 13.2/1.9) but as with the verbal fluency tasks, the results demonstrated Chinese speech production abilities in both groups that was sufficient for our categorical comparison with those who did not speak any Chinese.

*MR data acquisition*

Focal gray and white matter density was estimated on the basis of T1- weighted anatomical whole brain images acquired with a Siemens 1.5 T Sonata magnetic resonance imaging (MRI) scanner (Siemens Medical Systems, Erlangen, Germany). A T1-weighted three-dimensional (3D) MDEFT (modified driven equilibrium Fourier transform) sequence [Deichmann et al. 2004] was used to acquire 176 sagittal

*Neuroanatomical markers of speaking Chinese*

partitions with an image matrix of 256×224 yielding a final resolution of 1 mm<sup>3</sup> [repetition time (TR)/echo time (TE)/inversion time (TI), 12.24/3.56/ 530 ms]. The same scanner parameters and scanner hardware were used for the acquisition of all images.

*MR data preprocessing*

The structural brain images were preprocessed using Statistical Parametric Mapping software (SPM5 Wellcome Trust Centre of Imaging Neuroscience; <http://www.fil.ion.ucl.ac.uk/spm>) running under Matlab 6.5 (MathWorks, Natick, MA). The images were segmented into gray and white matter images using the unified segmentation algorithm, a generative model that combines tissue segmentation, bias correction and spatial normalization in the inversion of a single unified model. Estimating the model parameters (to give a maximum a posteriori solution) involves alternating among classification, bias correction and registration steps. This approach affords better results than serial applications of each component because conditional dependencies among the model parameters are modelled properly; i.e., registration and bias correction help the tissue classification, and the tissue classification helps the registration and bias correction [Ashburner and Friston 2005].

The resulting gray and white matter images were smoothed with an isotropic kernel of 8 mm at full-width half maximum. Smoothing widths of between 8 to 12 mm are generally recommended for VBM analyses to ensure that (a) each voxel contains the average amount of gray or white matter from around the voxel and (b) the data are normally distributed by the central limit theorem, thus increasing the validity of

*Neuroanatomical markers of speaking Chinese*

parametric statistical tests [Mechelli et al. 2005]. After smoothing, each voxel represents the local average amount of gray or white matter in the region, the size of which is defined by the smoothing kernel.

*MR data analysis*

The aim of the statistical analysis was to investigate how the ability to speak a tonal language (Chinese) correlated with local gray and white matter signal intensity. The same analysis was repeated with gray and white matter images.

Images from each of the three participant groups were modelled separately to assess differences in those who did and did not speak Chinese (see Table 1). As we were unable to manipulate number of languages spoken independently of first language, we factored out the number of languages spoken by modelling it as a confounding variable. The effect of age was also modelled as a confounding variable and we excluded the effects of global signal intensity using proportional scaling, so that we could focus the analysis on relative, regional differences in gray or white matter.

Regions with significant differences between Chinese versus non-Chinese speakers were identified using a statistical threshold of  $p < 0.05$  following correction for multiple comparison either across the whole brain or in our bilateral temporal regions of interest determined using a bilateral temporal mask image previously reported [Leff et al. 2008]. This mask image included Heschl's gyrus, planum temporale, the superior temporal gyrus (STG) and superior temporal sulcus (STS). It covered 7009 voxels, equal to 40 resolution elements or resells, and was created by manual segmentation of the bilateral temporal lobes on the single-subject canonical T1 brain

*Neuroanatomical markers of speaking Chinese*

template in MRICro [Rorden and Brett 2000]. We report the effects of each Chinese speaking group (native and non-native) relative to the European multilinguals who did not speak Chinese

**Results***Structural correlates of speaking Chinese*

Two regions were identified where gray and white matter density was higher in those who spoke Chinese than those who did not speak Chinese, see Figure 1. One was in the right anterior superior temporal gyrus and the underlying right middle longitudinal fasciculus extending anteriorly from Heschl's gyrus. The other was in the left posterior region of the insula, just medial to left Heschl's gyrus and the underlying white matter. The plots in Figure 2 illustrate that, in both areas, there was a categorical increase in gray and white matter density in Chinese speakers compared to non-Chinese speakers. There was no significant difference between the native and non-native Chinese speakers in these regions. Therefore despite our small sample of non-native Chinese speakers, there was evidence that gray and white matter in these regions was more similar to the native Chinese speakers than the multilinguals who did not speak Chinese, following a conservative random effects analysis in auditory processing areas.

The replication of these effects across native and non-native Chinese speakers demonstrates that the results were not driven by differences in ethnicity (see Table 2). No other significant gray or white matter effects were revealed in either the bilateral temporal lobes or across the whole brain. There was no significant difference in the

*Neuroanatomical markers of speaking Chinese*

reverse contrast, between European multilinguals > Chinese native and non-native speakers.

**Discussion**

In this structural imaging study we found that gray and white matter density in the right anterior temporal lobe and the left insula was significantly greater in those who spoke Chinese compared to those who did not. Importantly the effects were found in both native Chinese speakers and European subjects who learnt Chinese as a non-native language, illustrating that they were language related and not ethnicity effects. Although our study was not designed to pinpoint the exact level of processing that underlies the structural brain differences, we can nonetheless speculate, on the basis of prior studies, that these structural brain differences may reflect different levels of experience with tone processing.

Previous studies have associated the acquisition of foreign pitch patterns in word identification with greater gray matter volume in left Heschl's gyrus (HG) rather than in the regions identified here [Wong et al. 2008]. Pitch perception is clearly important in perceiving tonal contrasts, and structural differences in left Heschl's gyrus may moderate ease of acquisition especially in the early auditory processing stages as Wong and colleagues note. Nevertheless, Warren and colleagues [Warren et al. 2003b] propose that tracking of acoustic information streams occurs in anterior auditory areas, anterior to HG, whereas the segregation of sound objects (a crucial aspect of auditory scene analysis) depends on posterior areas. When they varied the pitch to produce a melody, they found greater functional activation in regions beyond

*Neuroanatomical markers of speaking Chinese*

1  
2  
3  
4  
5  
6  
7  
8  
9  
10  
11  
12  
13  
14  
15  
16  
17  
18  
19  
20  
21  
22  
23  
HG and PT, specifically in the superior temporal gyrus and planum polare. Their results support the view that there is a hierarchy of pitch processing in which the center of activity moves anterolaterally away from primary auditory cortex as the processing of melodic sounds proceeds. Tonal language speakers have to continuously track speech pitch changes, not only at a lexical level but also at a phrasal level to map the acoustic information onto meaning. Consistent with Warren et al.'s data [Warren et al. 2003b] our gray and white matter results in tonal language speakers point to the importance of temporal brain regions anterior to HG, specifically in the right temporal lobe.

Our structural imaging findings are also consistent with functional imaging studies of English speech comprehension which highlight the importance of the anterior superior temporal lobe when a suitable acoustic complexity of the speech signal is controlled. In native English speakers, intelligible speech results in left dominant anterior temporal lobe activation [Scott et al. 2000] along with activity in the homotopic right anterior temporal cortices [Spitsyna et al. 2006; Crinion and Price 2005].

43  
44  
45  
46  
47  
48  
49  
50  
51  
52  
53  
54  
55  
56  
57  
58  
59  
60  
The second brain region where our Chinese speakers showed significantly greater gray matter density compared with non-Chinese speakers was in a posterior region of the left insula, just medial to left Heschl's gyrus. The co-ordinates we have identified from structural data are similar to those shown to be involved in a functional imaging study of Mandarin speakers discriminating tones in Chinese words [Wong et al 2004], perceptual processing of utterances that convey information about a speaker's affective/emotional state by their 'tone' [Dietrich et al. 2008] and when participants listen to speech with high relative to low degrees of prosodic expression [Hesling et

*Neuroanatomical markers of speaking Chinese*

1  
2  
3  
4  
5  
6  
7  
8  
9  
10  
11  
12  
13  
14  
15  
16  
17  
18  
19  
20  
21  
22  
23  
24  
25  
26  
27  
28  
29  
30  
31  
32  
33  
34  
35  
36  
37  
38  
39  
40  
41  
42  
43  
44  
45  
46  
47  
48  
49  
50  
51  
52  
53  
54  
55  
56  
57  
58  
59  
60

al. 2005]. **Underlying this left posterior insula region we also found increased white matter in the left superior longitudinal fasciculus (SLF). Friederici (2009) argues that the SLF is crucial for the ability to process complex sentence structures. However, the functional significance of this pathway is hotly debated. Differentiation of the SLF from the arcuate fasciculus and their respective cortical projections (see Glasser and Rilling, 2008 for a meta-analysis) is not easily achieved by the current means of diffusion tensor imaging and interpretation of their functional roles must, therefore, await further empirical support. Nevertheless, our gray matter findings are consistent with previous studies that have associated the left posterior insula with the processing of tone in speech perception.**

Our aim was to identify brain regions where there are categorical differences between subjects who do and do not speak Chinese, irrespective of their ethnicity. We have identified 2 key regions in the right temporal and left insula cortex. As our Chinese speaking participants were all proficient in Chinese, we did not have sufficient variance within group to show a correlation between brain structure (gray/white matter density) and proficiency in Chinese perception and production tasks. Indeed, although our sample size of multilingual non-native Chinese speaking group was small, the fact that we observed structural differences in this group is likely to be a consequence of homogeneity in their proficiency, how they learnt Chinese and their daily use of Chinese (they were all on the same full time Masters course). Future studies are therefore required to investigate how gray and white matter changes within or between subjects, over the course of learning to speak Chinese. More detailed behavioral assessments would also help to establish whether the structural brain

*Neuroanatomical markers of speaking Chinese*

differences shown in this study are related to speech perception, production or comprehension abilities, or more general pitch perception skills. For example, investigation of musical abilities may be relevant as previous studies have shown that, irrespective of the age of onset of musical training, individuals with a musical abilities show a more robust response in the brain stem to differences in lexical pitch [Wong, Skoe et al.2007] and, as might be expected, they are also better at perceiving pitch patterns in a non-lexical context and are more adept at learning to use pitch patterns for lexical purposes [Wong Perrachione & Parrish 2007].

Finally, we note that previous studies have suggested that typological differences between tonal and non-tonal languages are associated with genetic differences in the populations that speak them [Dediu and Ladd 2007]. The fact that our group of non-native Chinese speakers showed gray and white matter differences relative to other European multilinguals in exactly the same regions as native Chinese speakers implicates language acquisition as an important source of structural brain differences in tonal language speakers too. Of course, we cannot determine from our cross-sectional study whether the gray and white matter differences we have identified are the result of having acquired a tonal language or facilitate the acquisition of a tone language. It is possible, but unlikely that the European multilinguals that learnt Chinese had differences in these brain regions. Resolution of this issue requires further suitably controlled, longitudinal structural studies of the acquisition of Chinese in non-native speakers.

**Conclusions**

*Neuroanatomical markers of speaking Chinese*

There are three conclusions that can be validly made from our results at this stage. First, they demonstrate that left insula and right superior temporal, gray and white matter densities are a marker of speaking Chinese in both native and non-native Chinese speakers. Second, they suggest an explanation for a previously reported structural difference between Chinese and non-Chinese speakers (namely, ability to speak a tonal language rather than ethnicity per se). Third, the location of the gray and white matter changes in right superior temporal lobe suggests that in speakers' of a tonal language this region is an important substrate for the crucial link between the pitch of words and their meanings.

For Peer Review

*Neuroanatomical markers of speaking Chinese*

## Reference List

Ashburner J, Friston KJ. Unified segmentation. *Neuroimage*. 2005; 26: 839-851.

Crinion J, Price CJ. Right anterior superior temporal activation predicts auditory sentence comprehension following aphasic stroke. *Brain* 2005.

Dediu D, Ladd DR. Linguistic tone is related to the population frequency of the adaptive haplogroups of two brain size genes, ASPM and Microcephalin. *Proc.Natl.Acad.Sci.U.S.A* 2007; 104: 10944-10949.

Deichmann R, Schwarzbauer C, Turner R. Optimisation of the 3D MDEFT sequence for anatomical brain imaging: technical implications at 1.5 and 3 T. *Neuroimage*. 2004; 21: 757-767.

Dietrich S, Hertrich I, Alter K, Ischebeck A, Ackermann H. Understanding the emotional expression of verbal interjections: a functional MRI study. *Neuroreport*. 2008;19(18):1751-5.

Draganski B, May A. Training-induced structural changes in the adult human brain. *Behav.Brain Res*. 2008; 192: 137-142.

Friederici AD. Pathways to language: fiber tracts in the human brain. *Trends in Cognitive Sciences*. 2009; 13(4), 175-181.

Gandour J, Dziedzic M, Wong D et al. Temporal integration of speech prosody is shaped by language experience: an fMRI study. *Brain Lang* 2003; 84: 318-336.

Gandour J, Wong D, Hsieh L, Weinzapfel B, Van Lancker D, Hutchins GD. A crosslinguistic PET study of tone perception. *J.Cogn Neurosci*. 2000; 12: 207-222.

Gaser C, Schlaug G. Brain structures differ between musicians and non-musicians. *J.Neurosci*. 2003; 23: 9240-9245.

Glasser MF, Rilling JK. DTI Tractography of the Human Brain's Language Pathways. *Cerebral Cortex* 2008;18: 2471-2482.

Goodglass H, Kaplan E. **The assessment of aphasia and related disorders.** Philadelphia: Lea and Febiger 1972

Hesling I, Dilharreguy B, Clément S, Bordessoules M, Allard M. (2005) Cerebral mechanisms of prosodic sensory integration using low-frequency bands of connected speech. *Hum Brain Mapp*.26(3):157-69.

Hsieh L, Gandour J, Wong D, Hutchins GD. Functional heterogeneity of inferior frontal gyrus is shaped by linguistic experience. *Brain Lang* 2001; 76: 227-252.

*Neuroanatomical markers of speaking Chinese*

- Hughes CP, Chan JL, Su MS. Apraxia in Chinese patients with right cerebral hemisphere lesions. *Arch.Neurol.* 1983; 40: 732-736.
- Kay J, Lesser R, Coltheart M. *Psycholinguistic Assessment of Language Processing in Aphasia (PALPA)*. Psychology Press, 2001.
- Kochunov P, Fox P, Lancaster J et al. Localized morphological brain differences between English-speaking Caucasians and Chinese-speaking Asians: new evidence of anatomical plasticity. *NeuroReport* 2003; 14: 961-964.
- Lattner S, Meyer ME, Friederici AD. Voice perception: Sex, pitch, and the right hemisphere. *Hum.Brain Mapp.* 2005; 24: 11-20.
- Lee H, Devlin JT, Shakeshaft C et al. Anatomical traces of vocabulary acquisition in the adolescent brain. *J.Neurosci.* 2007; 27: 1184-1189.
- Leff AP, Iverson P, Schofield T et al. Vowel-specific mismatch negativity responses in the anterior superior temporal gyrus: an fMRI study. *Cortex* 2008;
- Li, P., Sepanski, S., & Zhao, X. Language history questionnaire: A web-based interface for bilingual research. *Behav. Res. Methods* 2006; 38(2): 202-210
- Luo H, Ni JT, Li ZH, Li XO, Zhang DR, Zeng FG, Chen L. (2006) Opposite patterns of hemisphere dominance for early auditory processing of lexical tones and consonants. *Proc Natl Acad Sci U S A.* 103(51):19558-63.
- Maguire EA, Gadian DG, Johnsrude IS et al. Navigation-related structural change in the hippocampi of taxi drivers. *Proc.Natl.Acad.Sci.U.S.A* 2000; 97: 4398-4403.
- Meara P. *EFL vocabulary tests*. Wales University:Swansea Centre for Applied Language Studies., 1992.
- Mechelli A, Crinion JT, Noppeney U et al. Neurolinguistics: structural plasticity in the bilingual brain. *Nature* 2004; 431: 757.
- Mechelli A, Price, CJ, Friston KJ, Ashburner J (2005) *Voxel-Based Morphometry of the Human Brain: Methods and Applications*. *Current Medical Imaging Reviews* 1, 105-113
- Patterson RD, Uppenkamp S, Johnsrude IS, Griffiths TD. The processing of temporal pitch and melody information in auditory cortex. *Neuron* 2002; 36: 767-776.
- Rorden C, Brett M. Stereotaxic display of brain lesions. *Behav.Neurol.* 2000; 12: 191-200.
- Scott SK, Blank CC, Rosen S, Wise RJ. Identification of a pathway for intelligible speech in the left temporal lobe. *Brain* 2000; 123 Pt 12: 2400-6.
- Spitsyna G, Warren JE, Scott SK, Turkheimer FE, Wise RJ. Converging language streams in the human temporal lobe. *J.Neurosci.* 2006; 26: 7328-7336.

*Neuroanatomical markers of speaking Chinese*

1  
2  
3 Swinburn K, Baker G, Howard D. **CAT: The Comprehensive Aphasia Test**. New  
4 **York: Psychology Press**, 2005.

5  
6  
7 Tong Y, Gandour J, Talavage T, Wong D, Dziedzic M, Xu Y, Li X, Lowe M.  
8 Neural circuitry underlying sentence-level linguistic prosody. *Neuroimage*. 2005 Nov  
9 1; 28(2):417-28

10  
11  
12 Wang Y, Jongman A, Sereno JA. Dichotic perception of Mandarin tones by Chinese  
13 and American listeners. *Brain Lang* 2001; 78: 332-348.

14  
15  
16 Wang Y, Sereno JA, Jongman A, Hirsch J. fMRI evidence for cortical modification  
17 during learning of Mandarin lexical tone. *J.Cogn Neurosci*. 2003; 15: 1019-1027.

18  
19  
20 Warren JD, Uppenkamp S, Patterson RD, Griffiths TD. Analyzing pitch chroma and  
21 pitch height in the human brain. *Ann.N.Y.Acad.Sci*. 2003a; 999: 212-214.

22  
23  
24 Warren JD, Uppenkamp S, Patterson RD, Griffiths TD. Separating pitch chroma and  
25 pitch height in the human brain. *Proc.Natl.Acad.Sci.U.S.A* 2003b; 100: 10038-10042.

26  
27  
28 Warrier CM, Zatorre RJ. Right temporal cortex is critical for utilization of melodic  
29 contextual cues in a pitch constancy task. *Brain* 2004; 127: 1616-1625.

30  
31  
32 Wong PC, Parsons LM, Martinez M, Diehl RL. The role of the insular cortex in pitch  
33 pattern perception: the effect of linguistic contexts. *J.Neurosci*. 2004; 24: 9153-9160.

34  
35  
36 Wong PC, Skoe E, Russo NM, Dees T, Kraus N. Musical experience shapes human  
37 brainstem encoding of linguistic pitch patterns. *Nat Neurosci*. 2007a; 10(4):420-2.

38  
39  
40 Wong PC, Perrachione TK, Parrish TB. Neural characteristics of successful and less  
41 successful speech and word learning in adults. *Hum Brain Mapp*. 2007b; 28(10):995-  
42 1006

43  
44  
45 Wong PC, Warrier CM, Penhune VB et al. Volume of left Heschl's Gyrus and  
46 linguistic pitch learning. *Cereb.Cortex* 2008; 18: 828-836.

47  
48  
49 Zatorre RJ, Samson S. Role of the right temporal neocortex in retention of pitch in  
50 auditory short-term memory. *Brain* 1991; 114 ( Pt 6): 2403-2417.

51  
52  
53 Zatorre RJ, Gandour JT. Neural specializations for speech and pitch: moving beyond  
54 the dichotomies. *Philos Trans R Soc Lond B Biol Sci*. 2008; 363(1493):1087-104  
55  
56  
57  
58  
59  
60

*Neuroanatomical markers of speaking Chinese***Table Legends:****Table 1: Demographic details of the three multilingual groups.**

The table displays mean scores and standard deviations (SD) of the subject groups.

**Table 2: Brain regions with higher gray and white matter in Chinese speakers.**

Location of effects are given in x,y,z co-ordinates in MNI space. Z = Z score; GM = gray matter. WM = white matter

For Peer Review

*Neuroanatomical markers of speaking Chinese***Table 1: Demographic details of the three multilingual groups.**

<b>Group Details</b>	<b>Native Chinese</b>	<b>Europeans</b>	<b>English-Chinese</b>
<b>Number of subjects</b>	31	21	7
<b>Age (years)</b>	22.0 (3.2)	25.5 (2.1)	22.0 (1.9)
<b>Number of Languages</b>	2.9 (1.0)	2.7 (1.0)	3.9 (1.2)
<b>Age of bilingualism</b>	6.1( 3.7)	10.4 (5.1)	11.0 (3.3)
<b>English Verbal Fluency</b>	14.0 (5.4)	12.6 (3.9)	20.3 (6.8)
<b>English Picture Description</b>	29.2(6.4)	36.5 (10.4)	28.1(5.6)
<b>English Lexical Decision</b>	105.4 (8.3)	105.6 (7.0)	111.0 (1.3)
<b>English Vocabulary Test</b>	173.5 (34.1)	181.3 (27.7)	218.0 (11.9)
	Mean (SD)	Mean (SD)	Mean (SD)

*Neuroanatomical markers of speaking Chinese*

1  
2  
3  
4  
5  
6  
7  
8  
9  
10  
11  
12  
13  
14  
15  
16  
17  
18  
19  
20  
21  
22  
23  
24  
25  
26  
27  
28  
29  
30  
31  
32  
33  
34  
35  
36  
37  
38  
39  
40  
41  
42  
43  
44  
45  
46  
47  
48  
49  
50  
51  
52  
53  
54  
55  
56  
57  
58  
59  
60

For Peer Review

*Neuroanatomical markers of speaking Chinese***Table 2: Brain regions with higher gray and white matter in Chinese speakers.**

Brain Region	Main effect of Speaking Chinese		Native Chinese > European multilinguals		English-Chinese > European multilinguals	
	x y z	Z	x y z	Z	x y z	Z
<b>Right Temporal lobe</b>						
Anterior superior temporal lobe GM	54 14 -18	3.9	52 14 -20	4.7	54 16 -18	2.9
Middle longitudinal fasciculus WM	46 -2 -16	4.4	46 -4 -16	5.1	46 2 -20	3.3
	44 -16 -6	4.0	44 -14 -12	5.2	44 -16 -4	2.8
<b>Left Hemisphere</b>						
Long insula/transverse temporal GM	-36 -16 2	4.1	-34 -16 0	5.5	-38 -16 4	3.4
Superior longitudinal fasciculus WM	-48 -12 16	4.6	-46 -10 16	5.0	-50 -16 18	4.2

*Neuroanatomical markers of speaking Chinese*

1  
2  
3  
4  
5  
6  
7  
8  
9  
10  
11  
12  
13  
14  
15  
16  
17  
18  
19  
20  
21  
22  
23  
24  
25  
26  
27  
28  
29  
30  
31  
32  
33  
34  
35  
36  
37  
38  
39  
40  
41  
42  
43  
44  
45  
46  
47  
48  
49  
50  
51  
52  
53  
54  
55  
56  
57  
58  
59  
60

For Peer Review

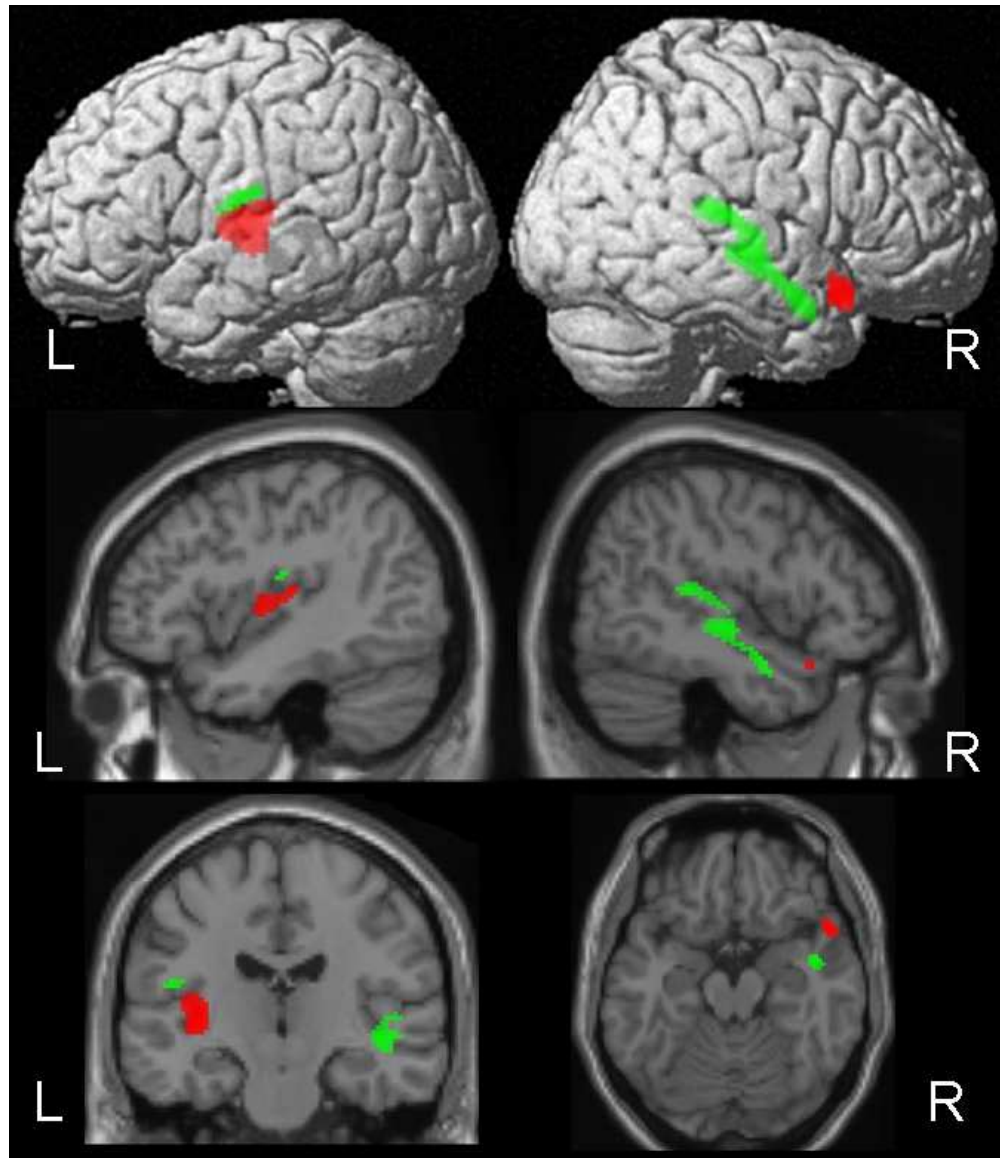


Figure 1: The effect of speaking Chinese.

The top row illustrates increased gray (red) and white (green) matter ( $p < 0.001$ , random effects analyses) for Chinese speakers relative to non-Chinese speakers, surface rendered onto a single-subject brain T1 template. The middle row displays sagittal projections and the third row coronal and axial projections. Details regarding the location and significance of results are given in Tables 2. L= left hemisphere; R= right hemisphere.

114x132mm (150 x 150 DPI)

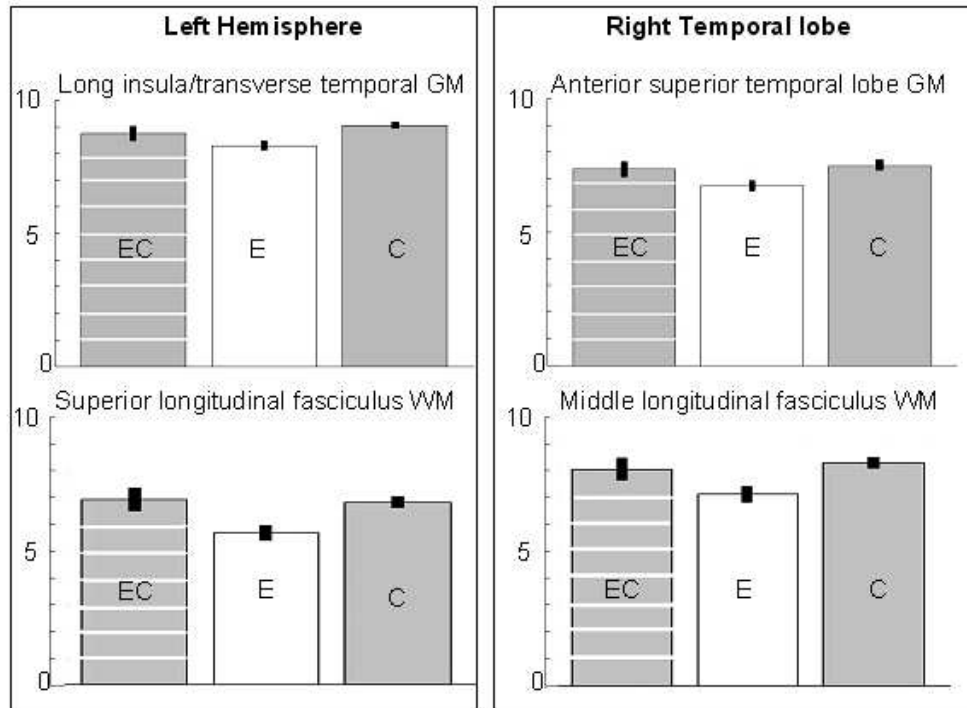


Figure 2: The effect of speaking Chinese.

The plots illustrate gray and white matter density in Europeans who do speak Chinese (EC), Europeans who do not speak Chinese (E) and native Chinese speakers (C) ( $p < 0.001$ , random effects analyses). The left column illustrates increased gray (top) and white (bottom) matter density in the left hemisphere. The right column displays plots of gray (top) and white (bottom) matter density in the right temporal lobe region. X axis – subject groups; Y axis- effect size at peak coordinates of interest. The error bars on the parameter estimates of gray matter correspond to 90% confidence intervals in SPM. Details regarding the location and significance of results are given in Tables 2.

155x119mm (96 x 96 DPI)